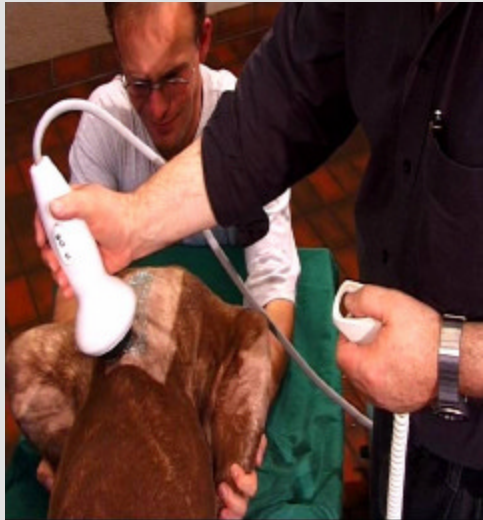

Back: the procedure

1. Sedate the animal
2. Clip the hair
3. Degrease the location
4. Apply enough gel
5. Choose the settings on the Equitron
E4/5-P240-SV500-R20
6. Direction
on the left and right side
paramedian dorsal to ventral
7. Start the therapy



Ileosacral problem

Tango

- Boxer, male, born 3.15.2000, 28 kg
- Age at the first ESWT: 10 months
- Problem: unstable back limb
- Diagnosis: unstable ileosacral joint
- Outcome: the back muscles are become much better



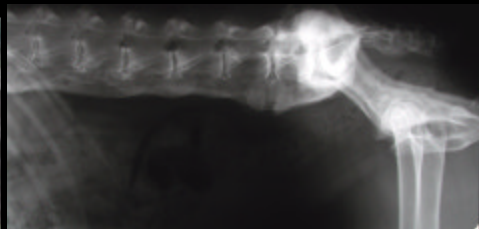
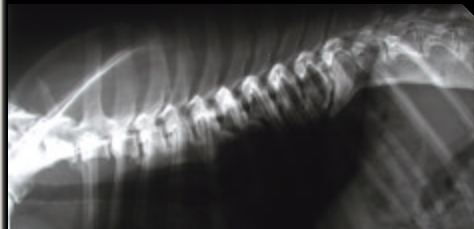
Spondylosis

Bella

- Boxer, female, born 3.22.1995, 32 kg
- Age at the first ESWT: 6 years
- Problem: beginning paralysis of the hind legs
- Diagnosis: spondylosis
- Outcome: see owner's reeport



4.18.2001 / 18228 / Bella / back



Spondylosis

Owner's report

Bella, female boxer, born March 22, 1995

Dog owners' observations before and after shock wave treatments

On April 9, 2001, nine days before the first treatment, Bella started to limp with the left hind leg. The first few days the limp was slight, however more noticeable whenever she had been resting for a while. During the days prior to the first limp we had not observed anything that could have caused some kind of trauma to a joint, a ligament or a muscle, she had not slipped, fallen or bumped against something, she had not had excessive exercise or wild romps with another dog. We cut the daily walks somewhat shorter and the situation remained more or less stable for a few days.

On April 14, during play with another dog in the garden, something started to hurt her very much. She did not want to walk any more, she just wanted to lie down in a corner. Steps seemed to represent a particular problem for her, we carried her up and down the steps between house and

garden. It was Easter and we had an appointment to see Dr. Hauri on April 18, therefore we saw to it that Bella rested a lot, we kept her warm and did not go on walks anymore. We just took (mostly carried) her down into the garden to relieve herself. She defecated only reluctantly and with some difficulty, small quantities and the faeces was quite flat, not round in shape. The situation remained stable until we saw Dr. Hauri on April 18, in fact, by then it seemed to have improved a tiny bit, but we had kept her very sedentary for the last 4 days.

Bella stayed in Beinwil for treatment from April 18 to 21.

When she returned home we slowly started our normal walking routine, after 4 days we were again up to over one hour of brisk walking in hilly territory in the morning, and another shorter walk in the afternoon. Now then the walks include running fast, or brief play sessions with another dog.

We did not see any limping anymore! After having rested for a longer period there was a very slight favouring of one leg during the first

few steps – and even of this we were not absolutely sure. It could also have been just some kind of stiffness. Eventually even the "stiffness" disappeared.

There are many steps on our property, inside the house as well as between house and garden. She took all steps with brisk, fluid motions, very evenly, not pausing, not changing legs - beautiful and extremely normal.

We saw to it that her faeces stayed on the softer side, by adding some shredded linseed to her food. Defecating slowly became easier, quantity and shape of the faeces turned back to normal in the course of 5 to 6 weeks, i.e. 3-4 evacuations a day, round (or close to) in shape.

On May 11 Bella received a second shock wave treatment. Quite frankly, we can not remember any specific differences between the situation immediately prior to May 11 and after. She continues to walk very well and there is no limp whatsoever.